

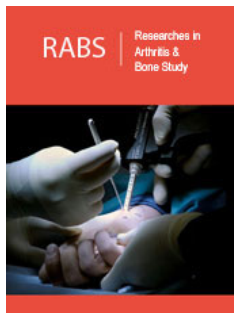
An Unusual Localization of Calcific Tendinitis: Flexor Digitorum Profundus

Rana Terlemez*

Department of Physical Therapy and Rehabilitation, Turkey

Clinical Image

A 34-year-old woman admitted to our clinic with pain, erythema and swelling on her 4th finger. She complained pain for 1 week with an acute onset. She did not report any history of prior trauma. Blood analysis was not appropriate with septic conditions. X-ray of the hand showed calcification over the volar aspect of the 4th metacarpophalangeal joint (Figure 1). Surgical excision confirmed our diagnosis. Calcific tendinitis of flexor digitorum profundus is a rare condition that can be misdiagnosed as septic arthritis, gout, acute fracture or tenosynovitis [1].



***Corresponding author:** Rana Terlemez,
Department of Physical Therapy and
Rehabilitation, Turkey

Submission: 📅 October 22, 2019

Published: 📅 November 14, 2019

Volume 1 - Issue 5

How to cite this article: Rana Terlemez. An Unusual Localization of Calcific Tendinitis: Flexor Digitorum Profundus. Res Arthritis Bone Study.1(5). RABS.000524.2019.

Copyright@ Rana Terlemez. Michaels, This article is distributed under the terms of the Creative Commons Attribution 4.0 International License, which permits unrestricted use and redistribution provided that the original author and source are credited.

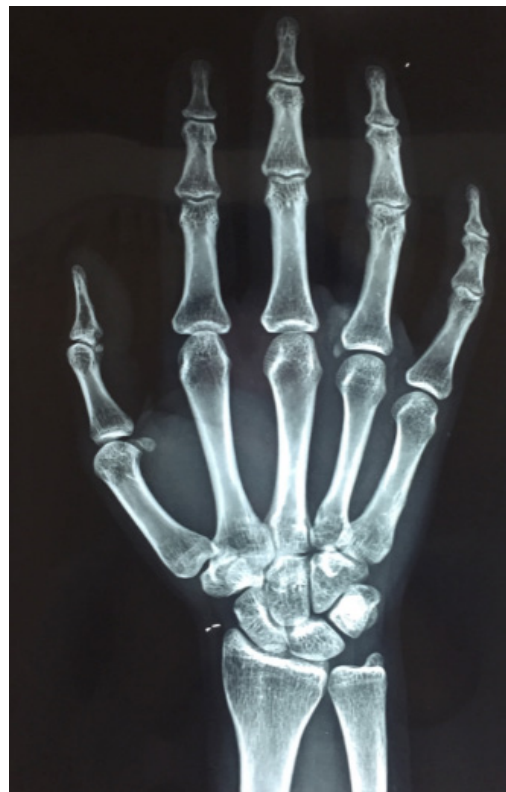

Figure 1: X-ray of the hand showed calcification over the volar aspect of the 4th metacarpophalangeal joint.

References

1. Huntley JS, Dougall TW (2003) Mistaken identity: Calcific tendinitis in the finger. Hosp Med 64(12): 747.