


# The Impact of the Mandible on the Knees-The Smylist® Explanation

Csillag Maria<sup>1</sup> and Kakar Ajay<sup>2\*</sup>

<sup>1</sup>Principal Author and creator of the Smylist concept, Aesthetic Dentist, Budapest, Hungary

<sup>2</sup>Supporting contributor, Periodontist, Mumbai, India

ISSN: 2637-7764



\*Corresponding author: Csillag Maria,  
1221 Budapest, Homezo U 40, Hungary

Submission: 📅 December 17, 2019

Published: 📅 December 19, 2019

Volume 4 - Issue 5

**How to cite this article:** Csillag M, Kakar A. The Impact of the Mandible on the Knees-The Smylist® Explanation. *Mod Res Dent.* 4(5). MRD.000597.2019.  
DOI: [10.31031/MRD.2019.04.000597](https://doi.org/10.31031/MRD.2019.04.000597)

**Copyright@** Csillag Maria, This article is distributed under the terms of the Creative Commons Attribution 4.0 International License, which permits unrestricted use and redistribution provided that the original author and source are credited.

## Abstracts

The musculoskeletal system of the body is connected by an intricate network of muscles and bones much like a spider's web. A disruption at any point can lead to a series of events which can be very damaging. This article presents how a disruption in the balance with the mandible and its muscles can lead to serious unilateral knee damage through a negative cascade of events that take place.

Keywords: Smylist; Mandible; Rotation; Knee; Unilateral; Joint; Deprogramming; Balance; Dentistry; Muscles; Musculoskeletal; Pain; Negative; Cascade; Events

## Introduction

The mandible is the mobile joint in the body where the bone works as a single unit with both the joints moving optimally and simultaneously. The mandible is the topmost mobile joint in the skeletal system and has a powerful impact on the entire body. The Smylist method is the first concept in dentistry that has studied the mandible in detail in a complex way as a part of the musculo skeletal apparatus, how it effects the entire musculo skeletal system and how it can be influenced positively or negatively. Hence the name "Negative Cascade Effect" in the Smylist concept [1]. It is important to understand and learn more about how the mandible moves. How the facial and skeletal muscles associated with the mandible function during mandibular movement. The muscles directly associated with the mandible are the masticatory muscles and the mimic muscles of the face and these muscles play a very critical role in the movement of the mandible. It is also important to note that these muscles are part of the entire musculature of the body and are interlinked with the rest of the body muscles. The entire musculature is thus inter-related, and this inter-relation is one of the strong foundations of the Smylist concept.

## The dentition and the musculo skeletal system

The human dentition is housed in the maxilla and the mandible. The maxillary teeth serve as a guide and stop for the mandibular teeth housed in the mandible which effectively is a guide and stop for the mandible. Ideally this movement of the mandible should be bilaterally symmetrical and all the involved muscles on the right and the left side should neither be over stretched and nor should they be in a state of spasm. If the maxillary teeth provide a stop at the right place the condyles will be appropriately placed in the fossae and the maxillary / mandibular relationship will be ideal. In this position all the involved muscles are also favorably placed. Unfortunately, the mandible is not always in such a place [2]. If the maxillary teeth do not provide an ideal stop in the right position, the mandible may get shifted to either the right or the left side. This shift or deviation is more appropriately termed as "rotated" in the Smylist concept. Since the two condyles are connected, they cannot possibly move independent of each other. Hence, a right rotated mandible will have the right condyle rotated and shifted towards the right side and the left condyle translated forward and rotated to the right side. It is also possible that the mandible may close too much if the maxillary teeth are protruded and do not provide a stop.

This is an over rotated mandible. The muscles of the body from head to toe work in unison, literally like a spider's web and hold the body in balance at all times [3]. If one muscle is over

stretched, some other muscles on the opposite side will be impacted and probably will contract constantly to maintain this body balance. If some muscles get inactive some muscles will become hyperactive. A muscle in a state of spasm due to constriction of the muscle will pull the given part of the body towards itself. This will cause a breach in the body balance and other muscles will create a forced body position to somehow maintain the overall body balance. Since the entire musculo skeletal system is connected to each other, all the muscles of the body get adjusted to maintain this state of balance [4]. The right or left rotated mandible causes a disruption of the body balance. In fact, this disruption is more pronounced due to the position of the mandible in the top portion of the body. It is the first mobile joint along the vertical axis. A rotated mandible leads to its associated muscles getting unilaterally over stretched or in a state of spasm. Certain muscles also get flattened because they are not used because of the rotated mandible [5].

A right rotated mandible will cause the muscles on the left side to be overstretched. These muscles impact the face and the signs can be clearly discerned for e.g. the naso labial fold which will become horizontally displaced on the side the mandible is rotated. For the body to be balanced properly when the mandible is rotated to either the left or the right, the musculo skeletal system comes into play. A right rotated mandible, contracting the muscles on the right side, makes it a reactive reflex compensation mechanism for the neck muscles on the left side to attempt to balance the body [6]. This in turn will create a cascade of events which will affect the entire body. Human beings are two legged and upright with the centre of gravity in the middle of the abdomen. This makes it very necessary to maintain the balance of the body. The first reaction of the musculo skeletal system is to attempt bring the body into a balanced state.

### Body balances and imbalances

The imbalance is caused due to the right rotated mandible and the muscles moving and holding the mandible in the rotated position [7]. The body attempts to balance itself in two planes. These are the horizontal and the antero posterior plane. The right rotated mandible which has caused over stretching of the muscles on the left side and a spasm of the muscles on the right side, including the neck muscles, are compensated and balanced by instinctively moving the right shoulder forward in the antero-posterior plane. This provides relief to the overstretched muscles neck muscles on the left side. Essentially the right shoulder rotates forward to balance the right rotated mandible. This is the first reaction of the musculo skeletal system to a right rotated mandible and vice versa.

The right rotated mandible also presents telltale signs on the face. One of the most classical signs is that of the nasio labial folds not being symmetrical. The right rotated mandible will cause the nasio labial fold on the left side to be more towards the vertical plane. The zygomaticus also flattens out on the left side. These telltale signs help in the diagnosis of a rotated mandible and also its severity. The Smylist examination and diagnostic system is based on how these folds and muscles get affected by specific imbalances in the mandible. As just explained this forward movement/rotation of

the right shoulder then leads to a further balancing attempt by the body. The balance is achieved but at a cost. Body loads are not equally distributed, and muscles can get into a constant state of spasm leading to constant chronic pain and restriction in movements. In the case of a right rotated mandible the right shoulder will move forward as a compensatory balancing mechanism.

Keeping the right shoulder in front like that is more comfortable to the individual. This now leads to the back muscles attempting to balance the body. The most common compensatory mechanism for a right forward rotated shoulder is the forward position of the left hip. When this individual stands or walks, the left hip joint will have to compensate to maintain body balance. The forward rotated and positioned left hip makes it almost impossible to walk in an equally balanced fashion. This makes the individual favor the left leg while walking or standing. This means that the right leg is overloaded. As this becomes a habit over a period of time (a few years) the right knee will get overused and start showing excessive wear and tear. Smylist has termed this as the "lean on" posture in which the individual usually stands constantly overloading one leg. This is the classical picture presented by patients who are in the mid-fifties and exhibit unilateral knee damage which more often than not needs knee replacement surgery. Smylist has termed this as the "negative cascade of events" originating from a right rotated mandible. A left rotated mandible will cause a similar but opposite situation with the left knee getting over used with degenerative changes.

### Conclusion

This sequence is the most probably manner in which the chain of events unfolds in a large majority of subjects. It has to be realized that there are a number of other parameters that come into play along with the severity of the rotation of the mandible. Depending upon these other interactions it is possible that the cascade of events may be different than what has been just described. Some of the back muscles or the shoulder muscles may get into a severe state of spasm which could be extremely painful and even lead to restricted movements of the arm and/or an imbalance in the gait and the ability to walk. A muscle in spasm becomes very painful over a very short period of time. The pain from a muscle in spasm can also get relieved to a considerable extent almost instantaneously. Smylist clinicians experience this phenomenon very often upon deprogramming the mandible which barely takes 10 to 15mins. Also, to be noted is the fact that when the fascia over the muscles gets overstretched due to a hyperactive muscle the area becomes tender and painful. The underlying nerves fibrils get hypersensitized which also leads to considerable discomfort. Muscles in spasm can also cause joints to actually get distorted due to the excessive pull leading to soreness and painful conditions.

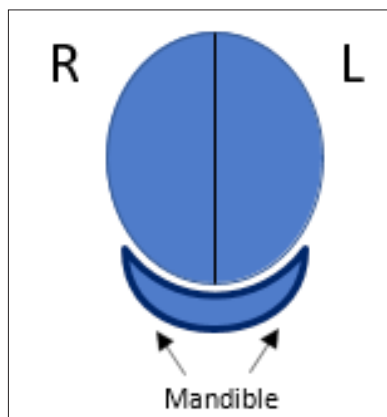
A very important aspect to be realized is that this sequence of events which has been described leads to a unilateral knee joint problem only over a period of time. This period of time is usually not a few days or weeks or months. The damage to one knee due to an overload will happen only over a few years of time. Hence it is a resultant of a chronic situation which leads to a slow damage/degeneration to one of the knees. Corrective treatment by the

orthopaedic will definitely help but it will not eliminate the cause of the problem. In all probability, since the overload will persist the corrective treatment will not last long and in 3 to 4 years a recurrence will start. If the rotated mandible is also corrected along with the treatment of the knee the primary cause of the problem will also be eliminated and the therapy will be far more successful. Hence it makes all the sense, for orthopaedic surgeons who treat such patients, to send these patients to a Smylist dentist to ascertain the extent and severity of the mandibular rotation, and if present, to ensure that the patient undergoes the necessary treatment to correct the deviation of the mandible.

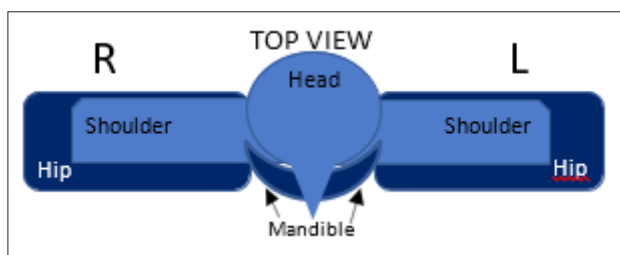
The other aspect to be considered is of prevention. As already explained, it takes a pretty long time before the rotated mandible will lead to a unilateral knee issue. The probability of a knee issue developing in the future due to a rotated mandible has to be worked out with a detailed history and clinical examination and understanding of the patient’s situation. When a Smylist dentist feels that the patient will sooner or later get into a degeneration of one of the knees. In such a situation the patient should be duly informed of the impending major knee joint problem and prophylactic correction of the rotated mandible should be strongly recommended.

**Graphic presentation**

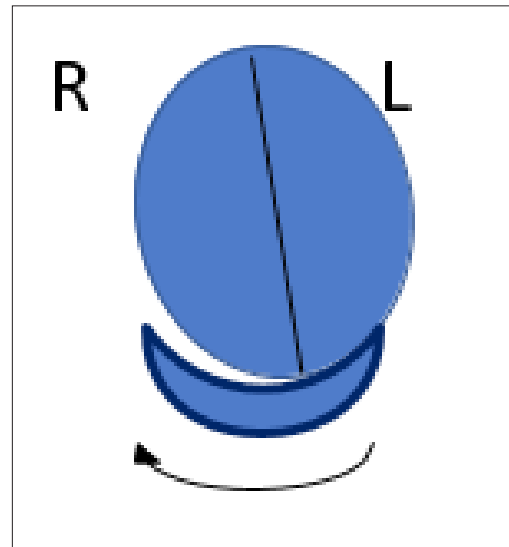
The above described example of the negative cascade of events triggered by a right rotated mandible is presented in a graphic form (Figure 1-8).




**Figure 1:** Front view of a balanced mandibular position.



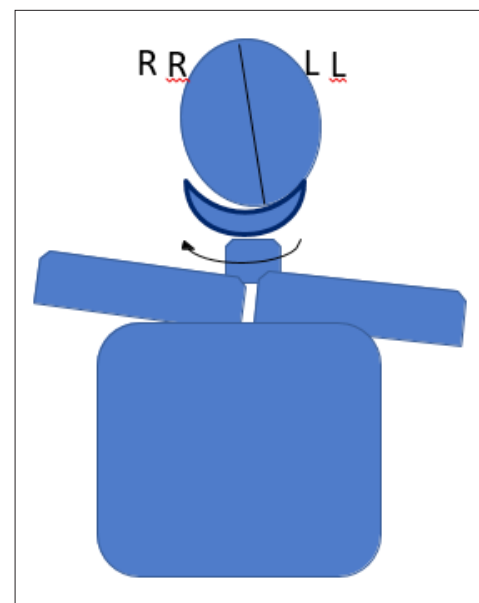
**Figure 2:** Top view of a balanced symmetrical body showing the shoulders and the hips from the head on position.



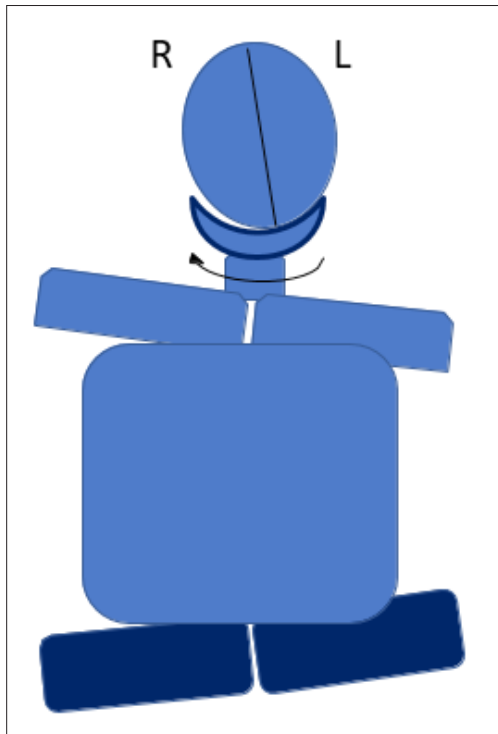
**Figure 3:** The right rotated mandible with the head tilted to the right.



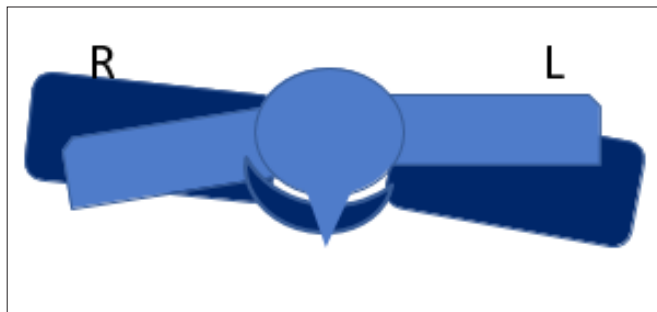
**Figure 4:** The right rotated mandible with the right shoulder rotated forward and the left shoulder slightly rotated backward-top view.



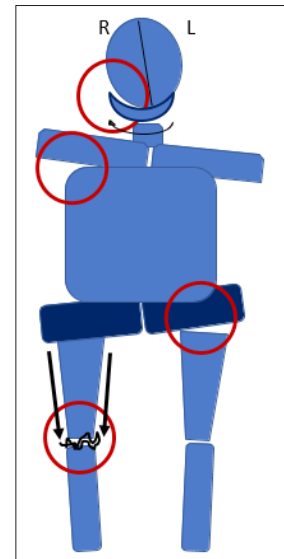
**Figure 5:** The right rotated mandible causing the right shoulder to be elevated and rotated forward - better visualized in Figure 4 which is a top view.



**Figure 6:** The elevated right shoulder makes the left hip shift upward. The more prominent effect is the forward rotation of the left hip which is better visualized in the top view in Figure 7.



**Figure 7:** Top view of forward rotated right shoulder leading to the left hip being rotated forward and the right hip slightly backward.



**Figure 8:** The left leg being favoured due to the forward rotated left hip leading to an overload of the right leg leading to degeneration of the right knee.

## References

1. Nguyen UD, Ayers DC, Li W, Harrold LR, Franklin PD (2016) Preoperative pain and function: profiles of patients selected for total knee arthroplasty. *J Arthroplasty* 31(11): 2402-2407.
2. Escobar A, Quintana JM, Arostegui I, Azkarate J, Guenaga JI, et al. (2003) Development of explicit criteria for total knee replacement. *Int J Technol Assess Health Care* 19(1): 57-70.
3. Katz JN (2014) Editorial: Appropriateness of total knee arthroplasty. *Arthritis Rheumatol* 66(8): 1979-1981.
4. Stucki S, Gkantidis N (2019) Assessment of techniques used for superimposition of maxillary and mandibular 3D surface models to evaluate tooth movement: A systematic review. *Eur J Orthod* pii: cjj075.
5. Rathee M, Jain P (2019) *Anatomy, Head and Neck, Lateral Pterygoid Muscle*. Stat Pearls Publishing.
6. Frisoli M, Edelhoff JM, Gersdorff N, Nicolet J, Braidot A, et al. (2017) Comparative study using video analysis and an ultrasonic measurement system to quantify mandibular movement. *Cranio* 35(1): 19-29.
7. Middendorf J, Albahrani S, Bonassar LJ (2019) Stribeck curve analysis of temporomandibular joint condylar cartilage and disc. *J Biomech Eng*.

For possible submissions Click below:

Submit Article