

# Resolution of the Coexisting Sarcoidosis after Treatment of Papillary Thyroid Metastases with Radioactive Iodine A Case Report

ISSN: 2578-0042



**Hossam El-Zeftawy\*, Belal Rammal and AbdulAziz El-Khiyami**

King Faisal Specialist Hospital and Research Center Jeddah, Saudi Arabia

## Introduction

The coexistence of Sarcoidosis (SA) with thyroid malignancy has been reported in many cases [1-3]. Sarcoid-like reaction has also been seen either within the vicinity of the tumor itself or within the regional lymph nodes draining its primary tumor [4]. Abnormal immune response has been suggested for the SA and/or its reactions when it coexists with thyroid diseases [5]. The presence of SA or sarcoid like lymph nodes and soft tissue infiltrations with thyroid cancer makes the diagnosis malignant recurrence and/or metastasis difficult, and a thorough investigation should be done to properly identify the recurrence and/or the metastasis from the coexisting SA or sarcoid-like manifestations. However, the prognosis and clinical course of SA or the sarcoid-like reaction after the treatment of thyroid malignancy has never been described in the literature. We are reporting a case of a 54-year-old lady diagnosed with metastatic papillary thyroid carcinoma with coexisting lymph nodes and pulmonary SA infiltrations. The patient had almost complete resolution of all SA manifestations after treatment of her metastatic papillary thyroid cancer with high dose radioactive iodine.

## Case Description

A 54-year-old lady with a history of long-standing diabetes mellitus, and hypertension was referred to our hospital with chronic shortness of breath, dry cough and hilar lymphadenopathy. Contrast Enhanced Computed Tomography (CECT) of the chest at presentation is displayed in Figure 1. The patient underwent mediastinoscopy and biopsy of mediastinal, neck and paratracheal lymph nodes. Histopathological results showed metastatic Papillary Thyroid Cancer (PTC) at the lymph nodes above the thyroid and granulomatous inflammation with focal necrosis and fibrosis from the mediastinal and paratracheal groups. Fine needle aspiration of thyroid gland nodule showed papillary thyroid carcinoma. The patient had no history of tuberculosis contact and all tuberculosis work up came back negative and so tuberculosis was excluded. After total thyroidectomy and lymph nodes dissection, pathologic examination confirmed the presence of multifocal thyroid papillary thyroid carcinoma with multiple lymph node metastases and granulomatous inflammation which showed negative fungal and tuberculosis stains. Post thyroidectomy I123 WB SPECT/CT scan is presented in Figure 2. Non stimulated Thyroglobulin (Tg) was not increased. The patient then received 200 mCi radioactive iodine treatment and her I131 post therapy scan again confirmed the results of the pre-therapy I123 dosimetric findings. Follow up CECT seven months later is shown in Figure 3 showing resolution of all sarcoid lymph nodes, lung infiltrations as well as the iodine avid peripheral lungs nodules.

**\*Corresponding author:** Hossam El-Zeftawy, King Faisal Specialist Hospital and Research Center Jeddah, Saudi Arabia

**Submission:**  February 02, 2024

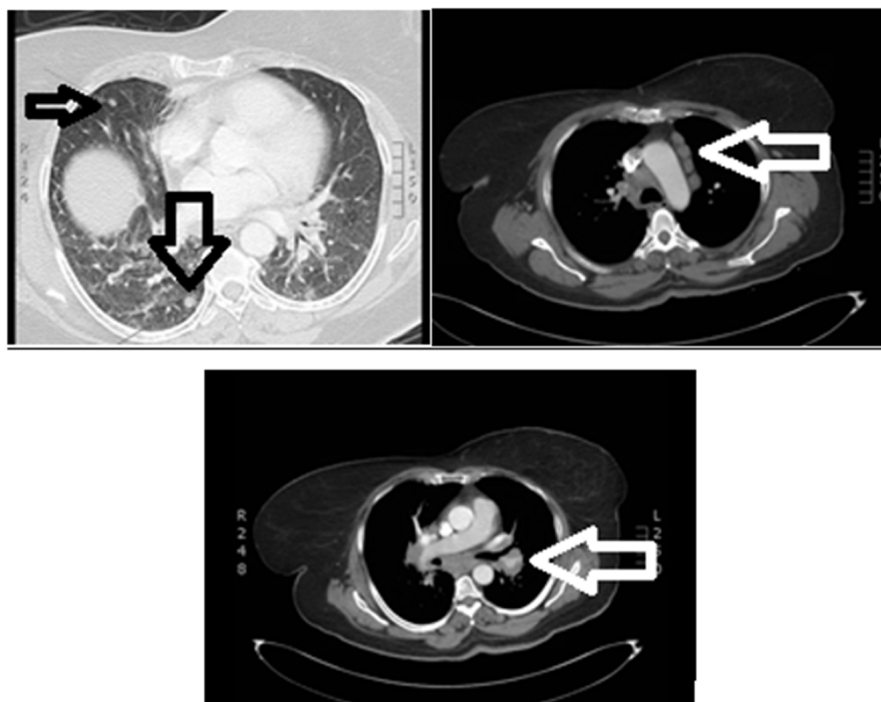
**Published:**  March 22, 2024

Volume 6 - Issue 3

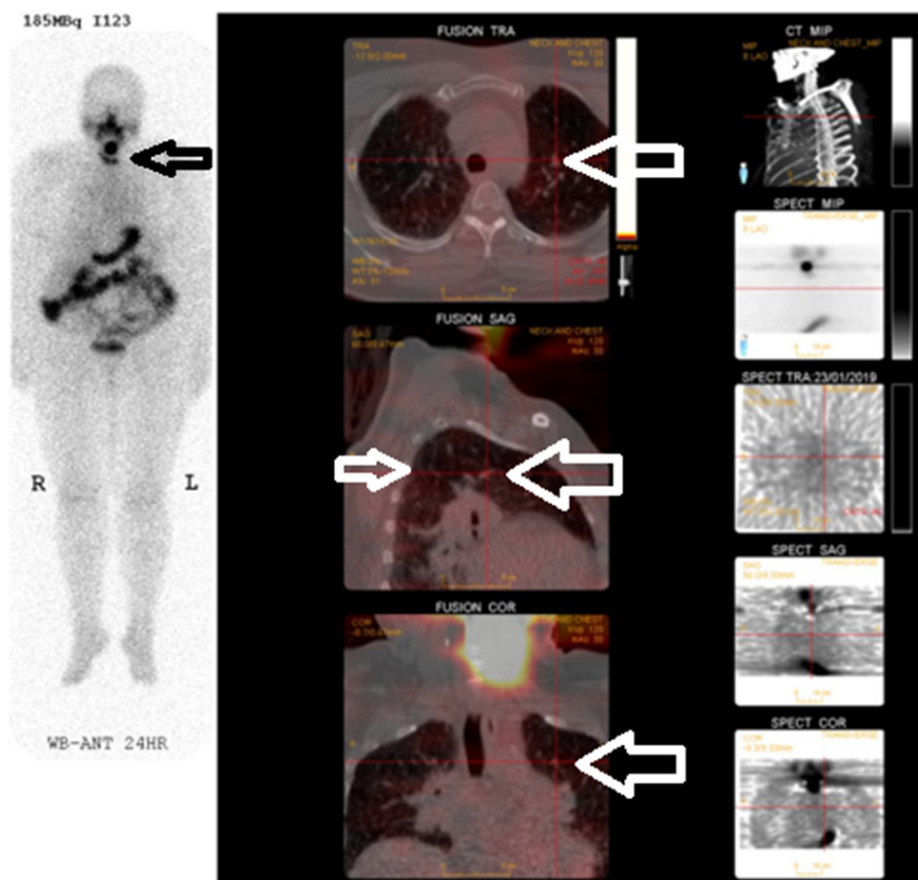
**How to cite this article:** Hossam El-Zeftawy\*, Belal Rammal and AbdulAziz El-Khiyami. Resolution of the Coexisting Sarcoidosis after Treatment of Papillary Thyroid Metastases with Radioactive Iodine A Case Report. Forensic Sci Add Res. 6(3). FSAR. 000642. 2024.

DOI: [10.31031/FSAR.2024.06.000642](https://doi.org/10.31031/FSAR.2024.06.000642)

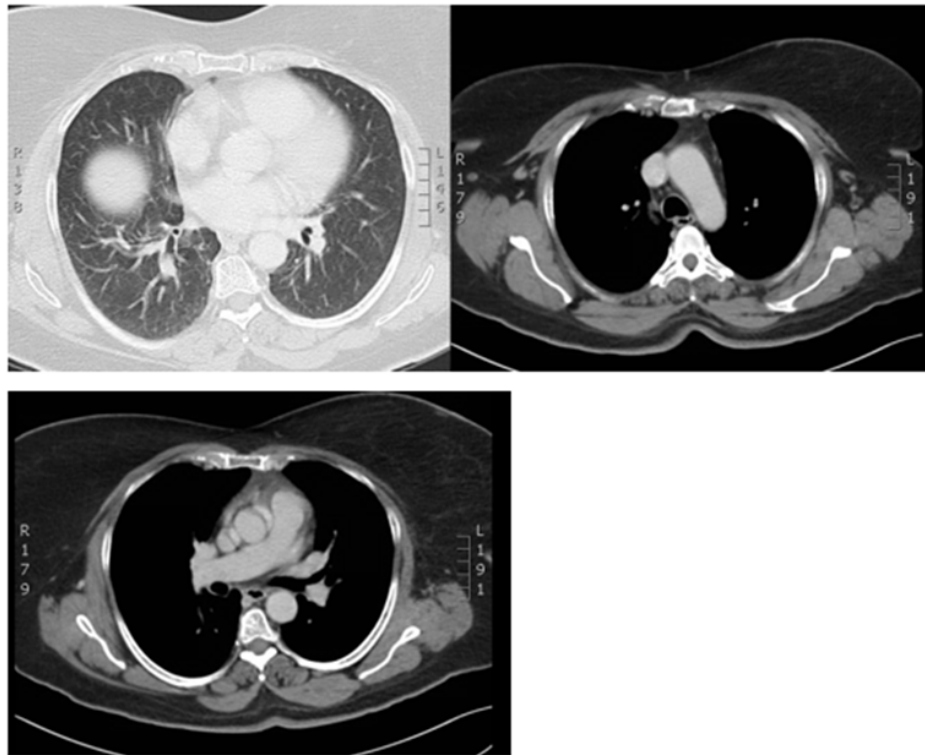
**Copyright@** Hossam El-Zeftawy, This article is distributed under the terms of the Creative Commons Attribution 4.0 International License, which permits unrestricted use and redistribution provided that the original author and source are credited.



**Figure 1:** Enumerable bilateral pulmonary nodules (black arrows) with right upper lobe faint interstitial opacities highly suspicious of sarcoid activity and numerous pathologically enlarged mediastinal lymph nodes up to 3.4 cm in size (white arrows).



**Figure 2:** Focal avid uptake of the tracer at the thyroid gland with multiple left neck nodes (black arrow) and diffuse bilateral military pulmonary metastases (white arrows).



**Figure 3:** Almost complete resolution of the pulmonary nodules and mediastinal lesions.

## Discussion

Sarcoidosis is a well-known granulomatous disorder of unknown etiology [1]. The co-existence of SA and/or sarcoid like reactions with PTC has been reported in several studies [1-3] which makes the diagnosis of malignant recurrence and/or its metastasis difficult without thorough investigations and multiple biopsies [4]. The defected immune system associated with SA and/or sarcoid like reactions can also be a reason for an abnormal serum Thyroglobulin (Tg) result, the key marker for follow up of recurrence of differentiated thyroid cancers [5]. In our case, the primary PTC was associated with neck lymph nodes and likely military bilateral pulmonary metastases. SA was diagnosed via pathologic examination of the biopsied mediastinal lymph nodes and transbronchial biopsy of the pulmonary infiltrate as well as the staging CECT criteria. The accumulation of the pre-therapy dosimetry I123 at the neck residual functioning thyroid tissue, neck lymph nodes and bilateral lungs nodules, directed the treatment towards the high dose I131 after surgical resection in spite of the non-diagnostic Tg level. 7 months after the radioactive iodine treatment,

the follow up CECT showed almost complete resolution of the neck, mediastinal lymph nodes and the pulmonary manifestations of SA as well as the bilateral lungs military nodules. This observation again stresses on the causal association between PTC and SA as a paraneoplastic syndrome or sarcoid like reactions to the primary tumor and directs towards the importance of treatment of the primary PTC disease even in the absence of abnormal serum Tg as a marker for recurrence in lieu of the defected immune system.

## References

1. Brincker H, Wilbek E (1974) The incidence of malignant tumors in patients with respiratory sarcoidosis. *Br J Cancer* 29(3): 247-251.
2. Salih AM, Fatih SM, Kakamad FH (2015) Sarcoidosis mimicking metastatic papillary thyroid cancer. *Int J Surg Case Rep* 16: 71-72.
3. Myint ZW, Chow RD (2015) Sarcoidosis mimicking metastatic thyroid cancer following radioactive iodine therapy. *J Community Hosp Intern Med Perspect* 5(1): 26360.
4. Shweta N, Sarcoid-Like Reactions. Meenakshi University, India, pp. 253.
5. Fazzi P, Fallahi P, Martina Ferrari S (2017) Sarcoidosis and thyroid autoimmunity. *Front Endocrinol* 8: 177.