



# Assessment of Palatine Suture Maturation By “Black Bone” Rmi-A Preliminary Feasibility Study



Nelson José Rossi\*, Rosa Carrieri Rossi, Nelson José Carrieri Rossi and Bruna Carrieri Rossi

Specialist in Orthodontics, University of Barcelona, Spain

\*Corresponding author: Nelson José Rossi, Specialist in Orthodontics, University of Barcelona, Spain

Submission: August 15, 2017; Published: July 12, 2018

## Abstract

**Objectives:** To determine the potential of “Black Bone” MRI as an alternative to CT in the maturation parameters of the palatine suture and identify the optimal time to perform orthodontic palatal expansion.

**Methods:** two patients from 10.3 and 25.9 years underwent “Black Bone” MRI. T1 and T2 weighted spin echo imaging were obtained in the axial plane in addition to routine cranial RMI. “Black Bone” datasets were subsequently compared to T2 weighted RMI for the visualisation medial palatine sutures by using a similar based method to evaluate suture fusion stages.

**Results:** Patient palatine sutures were consistently identified on “Black Bone” MRI as areas with different signal intensity according to the maturation stage, from complete separation of the halves to total fusion, as also found in the T2 weighted protocol. “Black Bone” MRI can be considered as an alternative to CT to assess the maturation of medial palatine suture for orthodontic purposes. Conclusions “Black Bone” MRI has considerable clinical potential as a nonionising alternative to CT in the assessment of the medial palatine suture.

### Key Points:

- Patient sutures appear hyperintense on “Black Bone” MRI
- Clearly different stages of suture fusion can be identified according to the age
- No ionising method can be used to find the optimal time to perform orthodontic palatal expansion.

Overall, “Black Bone” MRI offered an improved method of evaluation and provides a potential non-ionizing alternative to CT.

The sutures were identified as areas of increased signal intensity, easily distinguished from the signal void of the cranial bone. The sutures could be followed throughout their course in most cases.

**Keywords:** Magnetic resonance imaging; Radiation protection; Dentofacial deformities; Malocclusion

## Introduction

Transverse maxillary deficiency is a common orthodontic problem and is often accompanied by unilateral or bilateral posterior crossbite and dental crowding [1]. The best time to do the palatal expansion is in the anterior phase or during adolescence [2-7], since after this phase there may be a need for a complementary surgery [8] to weaken the bony bases, allowing the expansion. The most common approach is the use of a tooth-supported expander, with or without acrylic [9,10]. Some undesirable effects related to the age are: exaggerated inclination of the posterior teeth and lack of expansion of the middle third of the face as a result of the palatine and maxillary sutures ossification [3].

The ossification of the medial palatine suture starts from the palatine part and extends to the incisive foramen showing histological and radiographic changes [11]. The knowledge of the maturation stage of the medial palatine suture has great importance for the success of the palatine disjunction so that the verification of local conditions can only be done by imaging methods. The ideal pattern for studying the effects of palatine disjunction is concomitant computed tomography, since the morphological aspects and even the volume of the structures before and after the procedure can be evaluated [12,13].

Recently, a method of prognosis of palatal disjunction was described by the evaluation of ossification stages in concomitant computed tomography scans that help predict the success of this operation [14]. Despite the practicality and lower costs, the use of ionizing radiation in tomographies has been questioned by orthodontists [15] and the possibility of evaluating images of the ossification of the median palatine suture using nuclear magnetic resonance seems a promising field. The soft part of the sutures is formed

Recently, a method of prognosis of palatal disjunction was described by the evaluation of ossification stages in concomitant computed tomography scans that help predict the success of this operation [14]. Despite the practicality and lower costs, the use of ionizing radiation in tomographies has been questioned by orthodontists [15] and the possibility of evaluating images of the ossification of the median palatine suture using nuclear magnetic resonance seems a promising field. The soft part of the sutures is formed

by a layer of vascularized connective tissue that diverges from the calcified cortical of the bones that compose it. The relaxation times of these tissues in T1 and T2 produce the necessary contrast in the generated images [16], through the off-line post-processing in workstation of the previously obtained images of these patients.

Recently, a new regimen of examination has been described [17] in order to shorten the time and accentuate the contrast between skull sutures and other structures [18], called Black Bone RMI. There given in question allows the suppression of the sign of fat and water present in soft tissues and accentuates the visualization of the cortical bone, which appears in black. In addition, it is not necessary to inject radiological contrast that is invasive and can be dangerous for some patients. This method allows the visualization of points used in radiographic cephalometry [19] and allows the obtaining of 2D and 3D images with ease of access to the cranial sutures [20] and the acquisition time is smaller than the conventional resonance (around 4 minutes), which is beneficial to the patient, especially in children. Regarding Otorhinolaryngology, the treatment of transverse efficiency seems to have favorable effects in several aspects. Improvement in oral breathing and head posture [21] was verified in children treated with this methodology.

Improvement in hearing loss was verified in children subject to expansion by the influence on the muscular function of the auditory tube and improvement in the mobility of the tympanic membrane [22]. In addition, other general health benefits of children are related to treatment with palatal expansion, such as improvement of sleep quality and nocturnal enuresis [23-25]. Palatine atresia was present in 72.9% of patients who presented episodes considered to be a risk of death by parents or guardians related to the combination of apnea, color change, muscle tone, choking or coughing when compared to another group of transverse constriction depends on the maturation stage of the median of children who did not have these episodes [26]. Since the treatment palatine suture, which in turn may contribute too to rhinolaryngological treatment, seems important to establish previously the best occasion for its application.

For this reason we propose a method of evaluation of the median palatine suture without the use of ionizing radiation that can be used to establish the best moment for the treatment of expansion specially in circumpubertal individuals. The purpose of this research is to evaluate the possibility of using "Black Bone" magnetic resonance imaging for the planning of the palatal disjunction procedure without the use of ionizing radiation from CT.

## Materials and Methods

Patients Ethical approval was granted by the Brazil Educational Association (Associação Educativa do Brasil) Research Ethics Committee (Sao Paulo, Brazil) 48278115.8.0000.5141, for MRI examination in patients aged five years and older in whom conventional face/cranial base RMI were needed for other problems than diseases that could interfere in the sutural or bone maturation. Written informed consent from the participants and/or their parents was obtained.

Patients who had previously undergone surgery, had completed orthodontic treatment or had fixed orthodontic appliances were excluded. For this time, two volunteers with ages, were selected by age and sex to match the most approximated mean according to [1,27].

Both conventional and "Black Bone Imaging" were acquired on a 1.5T magnet resonance machine (Philips). Sagittal T1, T2 weighted spin echo and "Black Bone" image were obtained with image acquisition centered on the middle axial structure to permit visualization of the palatine suture.

- A. Sagittal T1 SE (includes skull and face)
- B. Axial T1 SE 4/1mm (thickness/space): from the chin to the top of the frontal sinus
- C. Axial T2 FSE with fat sat 4/1mm (thickness /space): from the chin to the top of the sinus front
- D. Coronal T1 4/1mm (thickness /space): from the bridge to the anterior wall of the sinus jaw
- E. Coronal T2 FSE with fat sat 4/1mm from the bridge to the anterior wall of the sinus jaw

### For "Black Bone" RMI has been used the following protocol:

Repetition time: 8.6ms, Echo Time: 4.2ms, Flip Angle: 5°, Scan FOV: 24cm, Phase Encode: 256, Frequency Encode: 256, Receive Bandwidth: 31.25, ZIP: 2,512, NEX: 2, ETL: 1, Slice width: 2.4mm, Space between slices: 1,2mm.

The mean acquisition time in the conventional in the "Black Bone" protocol was 3.5 minutes. Head orientation: Natural head position in all 3 planes of space with the image analysis software cursor positioned at the patient's midsagittal plane in both coronal and axial views, the long axis of the palate horizontal in the sagittal view.

The cross-sectional slice was used for sutural assessment after placing the horizontal line of the software along the palate. For subjects with more curved palate the suture was evaluated in two central cross-sectional slices.

Positioning parameters were used to evaluate the axial sections of the maxillary bones, palatine bones and the medial palatine suture. Through the software Radiant DICOM viewer (Mexidant, Poland) the DICOM files were processed for adjusting brightness, contrast and zoom and exported to the Jpeg file format. The images were evaluated by three researchers (RCR, NJCR, BCR) after a calibration for the parameters of interest and the images selected to illustrate the maturation phases. For this purpose the flowchart adapted from [15,28] was used, as can be seen in the flowchart.

## Results

At this time two patients could be identified at the center of the mean age and maturation stage of the suture 1, both in conventional MRI and in the "Black Bone".

## Conclusion

The Black Bone RMI protocol offers an advantage in relation to the time of acquisition of the conventional protocol and it is not intended to the emission of ionizing radiation from the computed tomography, being a viable alternative to establish the best alternative or the orthodontic expansion procedure of the palate. Based on this preliminary study. We are now continuing the research to a large patients in different stages and sexes to validate this method.

## References

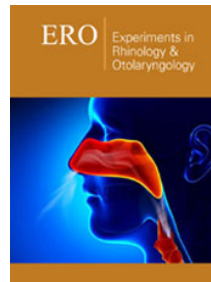
1. Angelieri F, Franchi L, Cevidanes LHS, McNamara JA (2015) Diagnostic performance of skeletal maturity for the assessment of palatal suture maturation. *Am J Orthod Dentofac Orthop* 148(6): 1010-1016.
2. Ramires T, Maia RA, Barone JR (2008) Nasal cavity changes and the respiratory standard after maxillary expansion. *Braz J Otorhinolaryngol* 74(5): 763-769.
3. Bishara SE, Jakobsen JR, Treder J, Nowak A (1997) Arch width changes from 6 weeks to 45 years of age. *Am J Orthod Dentofac Orthop* 111(4): 401-409.
4. Baccetti T, Franchi L, Cameron CG, McNamara JA (2001) Treatment timing for rapid maxillary expansion. *Angle Orthod* 71(5): 343-350.
5. Lagravère MO, Carey J, Toogood RW, Major PW (2008) Three-dimensional accuracy of measurements made with software on cone-beam computed tomography images. *Am J Orthod Dentofac Orthop* 134(1): 112-116.
6. Persson M, Thilander B (1977) Palatal suture closure in man from 15 to 35 years of age. *Am J Orthod* 72(1): 42-52.
7. Korbmacher H, Schilling A, Püschel K, Amling M, et al. (2007) Age-dependent three-dimensional microcomputed tomography analysis of the human midpalatal suture. *J Orofac Orthop* 68(5): 364-376.
8. Knaup B, Yildizhan F, Wehrbein H (2004) Age-related changes in the midpalatal suture. A histomorphometric study. *J Orofac Orthop* 65(2): 467-474.
9. Bell WH, Epker BN (1976) Surgical orthodontic expansion of the maxilla. *Am J Orthod* 70(5): 517-528.
10. Erverdi N, Okar I, Kucukkeles N, Arbak S (1994) A comparison of two different rapid palatal expansion techniques from the point of root resorption. *Am J Orthod Dentofac Orthop* 106(1): 47-51.
11. Weissheimer A, De Menezes LM, Mezomo M, Dias DM, De Lima EM, et al. (2011) Immediate effects of rapid maxillary expansion with Haas-type and hyrax-type expanders: a randomized clinical trial. *Am J Orthod Dentofac Orthop* 140(3): 366-376.
12. Ennes J, Consolaro A (2004) Sutura palatina mediana: avaliação do grau de ossificação em crânios humanos. *R Dental Press Ortod Ortop Fac* 9(5): 64-53.
13. Garrett BJ, Caruso JM, Rungcharassaeng K, Farrage JR, Kim JS, et al. (2008) Skeletal effects to the maxilla after rapid maxillary expansion assessed with cone-beam computed tomography. *Am J Orthod Dentofac Orthop* 134(1): 8.e1-8.e11.
14. Lione R, Ballanti F, Franchi L, Baccetti T, Cozza P (2008) Treatment and posttreatment skeletal effects of rapid maxillary expansion studied with low-dose computed tomography in growing subjects. *Am J Orthod Dentofac Orthop* 134(3): 389-392.
15. Angelieri F, Cevidanes LHS, Franchi L, Gonçalves JL, Benavides E, et al. (2013) Midpalatal suture maturation: Classification method for individual assessment before rapid maxillary expansion. *Am J Orthod Dentofac Orthop* 144(5): 759-769.
16. Miethke RRH (2013) Radiation risk-benefit in orthodontics. *Europ J Orthod* 35(1): 138-140.
17. Mazolla AA (2009) Ressonância magnética: princípios de formação da imagem e aplicações em imagem funcional. *Revista Brasileira de Física Médica* 23(1): 117-129.
18. Eley KA, McIntyre AG, Watt-Smith SR, Golding SJ (2012) "Black bone" MRI: a partial flip angle technique for radiation reduction in craniofacial imaging. *Br J Radiol* 85(1011): 272-278.
19. Eley KA, Watt-Smith SR, Golding SJ (2012) "Black bone" MRI: a potential alternative to CT when imaging the head and neck: report of eight clinical cases and review of the Oxford experience. *Br J Radiol* 85(1019): 1457-1464.
20. Eley KA, Watt-Smith SR, Golding SJ (2013) "Black Bone" MRI: a potential non-ionizing method for three-dimensional cephalometric analysis—a preliminary feasibility study. *Dentomaxillofac Radiol* 42(10): 20130236.
21. Eley KA, Watt-Smith SR, Sheerin F, Golding SJ (2014) "Black Bone" MRI: a potential alternative to CT with three-dimensional reconstruction of the craniofacial skeleton in the diagnosis of craniosynostosis. *Eur Radiol* 24(10): 417-426.
22. McNamara JA, Lione R, Franchi L, Angelieri F (2015) The role of rapid maxillary expansion in the promotion of oral and general health. *Prog Orthod* 16: 33.
23. Tecco S, Festa F, Tete S, Longhi V, Dattilio M (2005) Changes in head posture after rapid maxillary expansion in mouth-breathing girls: A Controlled Study. *Angle Orthod* 75(2): 171-176.
24. Villano A, Grampi B, Fiorentini R, Gandini P (2006) Correlations between rapid maxillary expansion (rme) and the auditory apparatus. *Angle Orthod* 76(5): 752-758.
25. Kilic N, Ali K, Oktay H, Selimoglu E (2008) Effects of rapid maxillary expansion on conductive hearing loss. *Angle Orthod* 78(3): 409-414.
26. Bazargani F, Jönsson-Ring I, Tryggve N (2016) Rapid maxillary expansion in therapy-resistant nuretic children: An orthodontic perspective. *Angle Orthod* 86(3): 481-486.
27. Rabasco J, Vigo A, Vitelli O, Noce S, Pietropaoli N, et al. (2016) Apparent life-threatening events could be a wake-up call for sleep disordered breathing. *Pediatr Pulmonol* 51(12): 1403-1408.
28. Landis JR, Koch GG (1977) The measurement of observer agreement for categorical data. *Biometrics* 33(1): 159-174.



Creative Commons Attribution 4.0  
International License

For possible submissions Click Here

[Submit Article](#)



### Experiments in Rhinology & Otolaryngology

#### Benefits of Publishing with us

- High-level peer review and editorial services
- Freely accessible online immediately upon publication
- Authors retain the copyright to their work
- Licensing it under a Creative Commons license
- Visibility through different online platforms