Crimson Publishers
Wings to the Research

Case Report

Delayed Emergence Unresponsive to Flumazenil After Remimazolam-Based General Anesthesia in an Elderly Patient with Preexisting Cerebrovascular Disease: A Case Report

Jaewoo Kim, Yeon Jae Song, Sungah Yoo and Kyungmi Kim*

Department of Anesthesiology and Pain Medicine, Anam Hospital, College of Medicine, Korea University, Republic of Korea

ISSN: 2639-0590



***Corresponding author:** Kyungmi Kim, Department of Anesthesiology and Pain Medicine, Anam Hospital, College of Medicine, Korea University, Seoul, Republic of Korea

Submission: November 09, 2026
Published: November 19, 2026

Volume 5 - Issue 1

How to cite this article: Jaewoo Kim, Yeon Jae Song, Sungah Yoo and Kyungmi Kim*. Delayed Emergence Unresponsive to Flumazenil After Remimazolam-Based General Anesthesia in an Elderly Patient with Preexisting Cerebrovascular Disease: A Case Report. COJ Rev & Res. 5(1). COJRR. 000605. 2026.
DOI: 10.31031/COJRR.2026.05.000605

Copyright@ Kyungmi Kim, This article is distributed under the terms of the Creative Commons Attribution 4.0 International License, which permits unrestricted use and redistribution provided that the original author and source are credited.

Abstract

Remimazolam is a novel benzodiazepine anesthetic characterized by rapid metabolism, hemodynamic stability, and presence of a specific benzodiazepine receptor antagonist, flumazenil; however, delayed emergence may still occur under certain clinical conditions. We describe a case of delayed emergence after general anesthesia with remimazolam in an 83-year-old patient undergoing reoperation for free-flap reconstruction following flap compromise after buccal cancer surgery. At the end of the surgery, flumazenil was administered to reverse the sedative effects of remimazolam; however, the patient remained unresponsive without improvement in consciousness. The delayed recovery may be explained by interindividual variability in carboxylesterase-1 activity and excessive neuro-suppression due to potential bispectral index underestimation of anesthetic depth during benzodiazepine-based anesthesia. In addition, benzodiazepine receptor antagonism does not necessarily restore activity of the arousal systems, which are essential for emergence from anesthesia. This case underscores the need for cautious titration when using remimazolam, particularly in elderly patients and those with pre-existing brain pathology.

Keywords: Delayed emergence; Elderly patients; General anesthesia; Remimazolam

Abbreviations: CES1: Carboxylesterase-1; CSHT: Context-Sensitive Half-Life; BIS: Bispectral Index

Introduction

Remimazolam is an ultra-short-acting benzodiazepine that is increasingly used for induction and maintenance of general anesthesia owing to its rapid, cytochrome P450-independent metabolism via hepatic Carboxylesterase-1 (CES1) [1,2], hemodynamic stability, short Context-Sensitive Half-Life (CSHT) [3], and the availability of a specific antagonist, flumazenil. Although its pharmacokinetic profile is generally characterized by high clearance and predictable emergence, recent clinical experience suggests that delayed recovery of consciousness can still occur, particularly in elderly patients and in prolonged anesthetic exposure. In previously reported cases of remimazolam-related delayed emergence, patients typically regained consciousness after flumazenil administration or experienced re-sedation following transient awakening. We report a case of delayed emergence following remimazolam-based anesthesia in an elderly patient in whom no recovery of consciousness was observed despite flumazenil administration.

Case Presentation

The patient was an 83-year-old man with a height of 163.9cm, body weight of 63.4kg. The patient's past medical history included hypertension and benign prostatic hyperplasia under

medication. The patient had a history of traumatic subarachnoid hemorrhage and right posterior inferior cerebellar artery infarction, which occurred 7 and 6 years before surgery, respectively. Brain computed tomography (Figure 1A) and magnetic resonance imaging demonstrated mild chronic cerebrovascular changes and age-related cerebral atrophy without acute intracranial pathology. The patient was alert and fully oriented, with no neurologic symptoms or regular use of psychoactive or sedative medications. Preoperative laboratory evaluation showed preserved renal function with an estimated glomerular filtration rate within the normal range, and there was no evidence of hepatic dysfunction or underlying liver disease. He was diagnosed with buccal cancer and was scheduled for tumor resection with tracheostomy and microvascular free-flap reconstruction. Induction was initiated using intravenous remimazolam at an infusion rate of 6mg/kg/h until the patient fell asleep, in accordance with the manufacturer's recommended dosing regimen, with rocuronium given as a 50mg intravenous bolus for neuromuscular blockade. We subsequently adjusted continuous infusions of remimazolam at 1mg/kg/h and remifentanil at 0.05-0.1μg/kg/min, aiming for bispectral index (BIS) values of approximately 40-60, a range commonly considered adequate for general anesthesia.

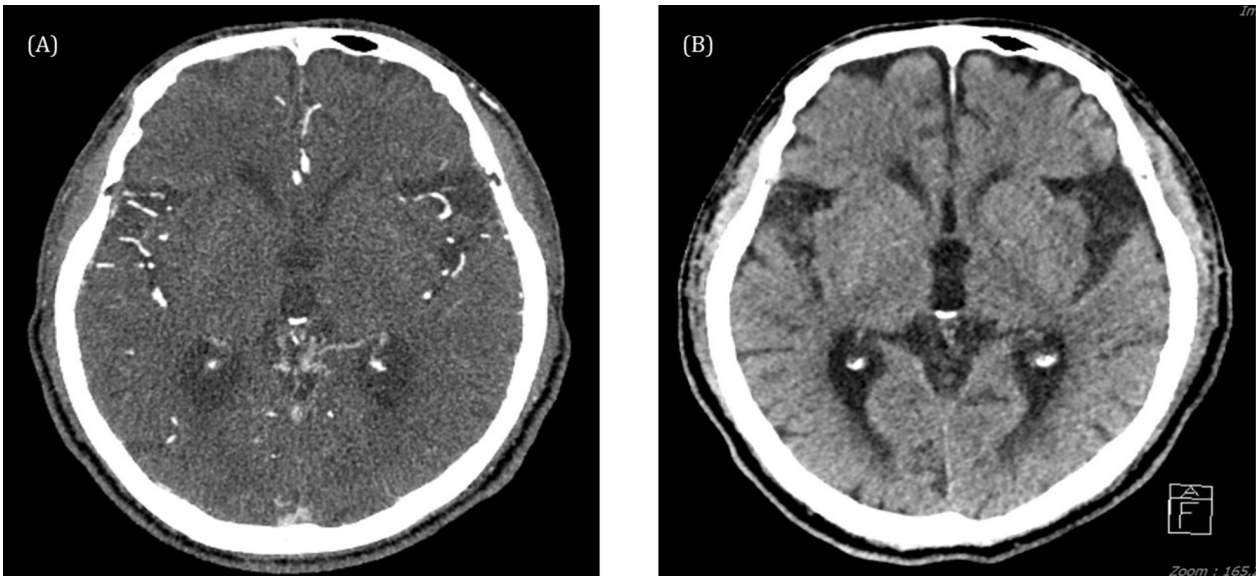

Figure 1: Preoperative and postoperative brain computed tomography. (A) Preoperative brain CT demonstrates mild chronic cerebrovascular changes and age-related cerebral atrophy, without acute intracranial pathology. (B) Postoperative brain CT reveals no acute intracranial pathology.

The surgery lasted approximately 6 hours, and the patient remained hemodynamically stable throughout the procedure. Given the anticipated risk of postoperative airway compromise after buccal cancer surgery, a tracheostomy was performed. The patient was admitted to the intensive care unit postoperatively and remained alert and fully oriented, and he was transferred to the general ward on postoperative day 1. On postoperative day 3, the patient developed flap compromise with color change, and emergency reoperation for salvage and reconstruction was performed. Anesthesia was induced and maintained using the same anesthetic regimen as in the previous surgery, with infusions of remimazolam at 6mg/kg/h for induction and 1mg/kg/h for maintenance, and remifentanil administered as a continuous infusion at 0.05-0.1μg/ kg/ min and rocuronium given as a 50mg intravenous bolus followed by a continuous infusion at 20mg/h. The surgery lasted approximately 9 hours, during which hemodynamics remained relatively stable, with mean arterial pressure generally maintained above 70mmHg, BIS values maintained at approximately 40-55, and core temperature ranging from 35.5 °C to 36.3 °C. At the end of surgery, sugammadex 200mg and flumazenil 300μg were administered intravenously to reverse remimazolam-induced sedation and neuromuscular blockade. Intravenous bolus nicardipine (total 1800mcg) and esmolol 10mg were administered to control the elevated blood pressure. Although spontaneous respiration had returned, the patient remained unresponsive to verbal and pain stimuli, with the BIS value remaining at 70.

Despite the additional administration of 150μg of flumazenil, no improvement in consciousness was observed, and the BIS remained around 70 without further increase. As vital signs and respiratory status were stable, the patient was transferred to the intensive care unit for close monitoring. Postoperative laboratory evaluations, including electrolytes, blood glucose, and arterial blood gas analysis, revealed no significant abnormalities. Given the patient's pre-existing cerebrovascular history, including traumatic subarachnoid hemorrhage and cerebral infarction, brain computed tomography (Figure 1B) and neurological consultation were performed but revealed no acute intracranial pathology. The patient was managed in the intensive care unit, and consciousness recovered spontaneously 9 hours after surgery, after which he followed commands and regained full orientation without

Copyright © Kyungmi Kim

neurologic deficit. He was subsequently transferred to the general ward on postoperative day 1 and discharged without residual neurologic abnormalities.

Discussion

Remimazolam has been increasingly incorporated into general anesthesia practice in countries where it is approved, because it is an ultra-short-acting benzodiazepine with a specific antagonist, flumazenil. In Japanese randomized trials, delayed emergence was reported in 1.3-8.0% of patients [4,5], and in most trial descriptions delayed cases typically responded promptly to flumazenil without clinically notable re-sedation. Only a few case reports have described postoperative long-term delayed emergence with resedation after flumazenil administration [6-8], and recent observations in intensive care unit patients receiving continuous remimazolam infusion for more than 24 hours have similarly demonstrated unexpectedly elevated plasma remimazolam concentrations and delayed awakening compared with predicted pharmacokinetic profiles [9]. Remimazolam is an ultra-short-acting benzodiazepine that produces hypnosis and sedation via positive allosteric modulation of the gamma-aminobutyric acid type A receptor at the benzodiazepine binding site, thereby increasing inhibitory neurotransmission, enhancing chloride influx, promoting neuronal hyperpolarization, and suppressing cortical and thalamic network activity [10,11]. Delayed emergence after remimazolam anesthesia may be explained by pharmacokinetic characteristics related to its CES1-mediated metabolism. Remimazolam is rapidly hydrolyzed by hepatic CES1, rather than cytochrome P450 enzymes, to an inactive metabolite, and this pathway is generally associated with high clearance and fast recovery [1,2].

Remimazolam demonstrates favorable pharmacokinetic characteristics, including a CSHT of approximately 7.5 minutes, and has been reported to reach a plateau in CSHT after approximately 2 hours of continuous infusion, indicating a relatively stable recovery profile even during extended administration [3]. However, pharmacokinetic alterations have been observed in patients with impaired hepatic function. In individuals with severe hepatic dysfunction, systemic clearance of remimazolam decreases by approximately 38.1%, and the emergence time has been reported to be nearly twice as long as that observed in patients with normal hepatic function (8.0min vs 16.7min) [12]. In addition, the activity of CES1, the primary enzyme responsible for remimazolam metabolism, is known to exhibit considerable interindividual variability, and CES1 activity is generally higher in women than in men [13,14]. Consequently, routine liver function tests alone may not adequately reflect the metabolic capacity relevant to remimazolam elimination. Benzodiazepines are associated with reduced long-range cortical effective connectivity and alterations in thalamocortical circuit dynamics [15-17], producing a pattern of neural suppression distinct from that of propofol and volatile anesthetics, which generate frontal alpha and slow-delta oscillations on electroencephalography [18,19]. Because BIS is derived from processed frontal electroencephalography signals largely developed and validated in propofol- and volatile-based anesthesia [20-22], its reliability may be reduced during benzodiazepine-dominant anesthesia [23,24].

Accordingly, several clinical studies have reported that BIS values during remimazolam anesthesia tend to remain higher than those observed during propofol anesthesia at comparable hypnotic depth [25-27], which is consistent with previous midazolam studies showing BIS values around 60 during general anesthesia despite adequate hypnotic depth [15]. Consequently, BIS values may remain relatively high despite substantial cortical suppression, and a BIS value of 40-60, which is considered adequate surgical anesthesia depth [21,22], does not necessarily indicate adequate anesthesia but may reflect excessive neurodepression. Importantly, reversal of benzodiazepine effects does not guarantee immediate recovery of consciousness because emergence is a systems-level process requiring reintegration of corticothalamic activity and re-engagement of arousal pathways [28-31], including the orexinergic hypothalamic pathway [32], ventral tegmental area pathway [33,34] and locus coeruleus noradrenergic system [35,36]. In patients with advanced age, chronic cerebrovascular changes, or prior intracranial injuries, baseline arousal network reserve may be reduced, allowing the brain to remain in a low-arousal state even after removal of pharmacologic inhibition.

Conclusion

Delayed emergence after anesthesia with remimazolam may occur despite rapid CES1-mediated metabolism of remimazolam due to limited hepatic clearance capacity for remimazolam, excessive neurodepression due to potential BIS underestimation of anesthetic depth during benzodiazepine-based anesthesia, and the inability of benzodiazepine receptor antagonism to directly reactivate the ascending reticular activating system; therefore, particular caution is warranted in elderly patients and those with pre-existing structural or cerebrovascular brain disease, in whom reduced cerebral reserve may further prolong recovery of consciousness.

Acknowledgement

We would like to acknowledge the generous support provided by Korea University Anam Hospital (2022AN0283).

References

1. Murrell DE, Harirforoosh S (2025) Clinical pharmacokinetics, pharmacodynamics, and drug interactions of remimazolam. European Journal of Drug Metabolism and Pharmacokinetics 50(6): 449-460.
2. Schmalix W, Petersen KU, Pesic M, Stohr T (2024) The metabolism of the new benzodiazepine remimazolam. Current Drug Metabolism 25(2): 164-173.
3. Luo H, Zhou C, Qu Y, Kuang X (2025) Research progress on the clinical application of remimazolam outside the operating room: A review of pharmacological characteristics, clinical effects, and safety. Clinical Pharmacology 17: 329-337.
4. Xiao G, Zhang Y, Yang J, He J, Zhang Y, et al. (2026) Remimazolam inhibits neuronal apoptosis, inflammation, and ferroptosis in cerebral infarction via promoting trim67-mediated degradation of acsl4. Journal of Biochemical and Molecular Toxicology 40(2): e70699.

Copyright © Kyungmi Kim

5. Doi M, Hirata N, Suzuki T, Morisaki H, Morimatsu H, et al. (2020) Safety and efficacy of remimazolam in induction and maintenance of general anesthesia in high-risk surgical patients (ASA class III): Results of a multicenter, randomized, double-blind, parallel-group comparative trial. Journal of Anesthesia 34(4): 491-501.
6. He G, Shi C, Gao W (2026) Re-sedation using remimazolam anesthesia in patients with multiple injuries during recovery: A case report and literature review. Frontiers in Medicine 12: 1702891.
7. Takemori T, Oyama Y, Makino T, Hidaka S, Kitano T (2022) Long-term delayed emergence after remimazolam-based general anesthesia: A case report. JA Clinical Reports 8(1): 86.
8. Yamamoto T, Kurabe M, Kamiya Y (2021) Re-sleeping after reversal of remimazolam by flumazenil. Journal of Anesthesia 35(2): 322.
9. Saito J, Hirota K (2026) Discontinuation of the development of remimazolam for ICU sedation in Japan: Background and rationale. Journal of Intensive Care 14(1): 15
10. Sigel E, Buhr A (1997) The benzodiazepine binding site of GABAA receptors. Trends in Pharmacological Sciences 18(11): 425-429.
11. Whizar V, Garnica C, Gastelum R (2016) Remimazolam: A new ultra short acting benzodiazepine. Journal of Anesthesia and Critical Care 4(6): 10166.
12. Stohr T, Colin PJ, Ossig J, Pesic M, Borkett K, et al. (2021) Pharmacokinetic properties of remimazolam in subjects with hepatic or renal impairment. British Journal of Anaesthesia 127(3): 415-423.
13. Vree TB, Dammers E, Ulc I, Horkovics-Kovats S, Ryska M, et al. (2003) Differences between lovastatin and simvastatin hydrolysis in healthy male and female volunteers: Gut hydrolysis of lovastatin is twice that of simvastatin. The Scientific World Journal 3: 1332-1343.
14. Patrick KS, Straughn AB, Minhinnett RR, Yeatts SD, Herrin AE, et al. (2007) Influence of ethanol and gender on methylphenidate pharmacokinetics and pharmacodynamics. Clinical Pharmacology and Therapeutics 81(3): 346-353.
15. Ferrarelli F, Massimini M, Sarasso S, Casali A, Riedner BA, et al. (2010) Breakdown in cortical effective connectivity during midazolam-induced loss of consciousness. Proceedings of the National Academy of Sciences of the United States of America 107(6): 2681-2686.
16. Judge O, Hill S, Antognini JF (2009) Modeling the effects of midazolam on cortical and thalamic neurons. Neuroscience Letters 464(2): 135-139.
17. Sohal VS, Keist R, Rudolph U, Huguenard JR (2003) Dynamic GABA(A) receptor subtype-specific modulation of the synchrony and duration of thalamic oscillations. Journal of Neuroscience 23(9): 3649-3657.
18. Purdon PL, Sampson A, Pavone KJ, Brown EN (2015) Clinical electroencephalography for anesthesiologists: Part I: Background and basic signatures. Anesthesiology 123(4): 937-960.
19. Akeju O, Westover MB, Pavone KJ, Sampson AL, Hartnack KE, et al. (2014) Effects of sevoflurane and propofol on frontal electroencephalogram power and coherence. Anesthesiology 121(5): 990-998.
20. Glass PS, Bloom M, Kearse L, Rosow C, Sebel P, et al. (1997) Bispectral analysis measures sedation and memory effects of propofol, midazolam, isoflurane, and alfentanil in healthy volunteers. Anesthesiology 869(4): 836-847.
21. Singh H (1999) Bispectral index (BIS) monitoring during propofolinduced sedation and anaesthesia. European Journal of Anaesthesiology 16(1): 31-36.
22. Song D, Joshi GP, White PF (1997) Titration of volatile anesthetics using bispectral index facilitates recovery after ambulatory anesthesia. Anesthesiology 87(4): 842-848.
23. Ibrahim AE, Taraday JK, Kharasch ED (2001) Bispectral index monitoring during sedation with sevoflurane, midazolam, and propofol. Anesthesiology 95(5): 1151-1159.
24. Kuizenga K, Wierda JM, Kalkman CJ (2001) Biphasic EEG changes in relation to loss of consciousness during induction with thiopental, propofol, etomidate, midazolam or sevoflurane. British Journal of Anaesthesia 86(3): 354-360.
25. Shiraishi T, Yahagi M, Yoshida M, Yawata M, Kurokawa H, et al. (2025) Comparison of bispectral index and patient state index during general anesthesia with remimazolam. BMC Anesthesiology 25(1): 566.
26. Yang C, Jiao J, Nie Y, Shao W, Zhang H, et al. (2024) Comparison of the bispectral indices of patients receiving remimazolam and propofol for general anesthesia: A randomized crossover trial. Anaesthesia Critical Care and Pain Medicine 43(3): 101377.
27. Choi BM, Lee JS, Kim KM, Bang JY, Lee EK, et al. (2023) Frequency and characteristics of patients with bispectral index values of 60 or higher during the induction and maintenance of general anesthesia with remimazolam. Scientific Reports 13(1): 9992.
28. Tzabazis A, Miller C, Dobrow MF, Zheng K, Brockutne JG (2015) Delayed emergence after anesthesia. Journal of Clinical Anesthesia 27(4): 353-360.
29. Brown EN, Lydic R, Schiff ND (2010) General anesthesia, sleep, and coma. New England Journal of Medicine 363(27): 2638-2650.
30. Lee U, Muller M, Noh GJ, Choi B, Mashour GA (2011) Dissociable network properties of anesthetic state transitions. Anesthesiology 114(4): 872-881.
31. Cascella M, Bimonte S, Di Napoli R (2020) Delayed emergence from anesthesia: What we know and how we act. Local and Regional Anesthesia 13: 195-206.
32. Kelz MB, Sun Y, Chen J, Meng QC, Moore JT, et al. (2008) An essential role for orexins in emergence from general anesthesia. Proceedings of the National Academy of Sciences of the United States of America 105(4):1309-1314.
33. Solt K, Van Dort CJ, Chemali JJ, Taylor NE, Kenny JD, et al. (2014) Electrical stimulation of the ventral tegmental area induces reanimation from general anesthesia. Anesthesiology 121(2): 311-319.
34. Solt K, Cotten JF, Cimenser A, Wong KF, Chemali JJ, et al. (2011) Methylphenidate actively induces emergence from general anesthesia. Anesthesiology 115(4): 791-803.
35. Wang D, Huang Y, Wang X, Chen X, Li J, et al (2020) Circadian differences in emergence from volatile anaesthesia in mice: involvement of the locus coeruleus noradrenergic system. British Journal of Anaesthesia 125(4): 548-559.
36. Li L, Rana AN, Li EM, Wells BA, Kenmochi SJ, et al. (2025) Noradrenergic tuning of arousal is coupled to movement transitions. Cell Reports

Copyright © Kyungmi Kim