

Radial Artery Pseudoaneurysm with Thrombosis- A Case without Trauma or Anterior Local Surgery

Márcio Luís Duarte* and Élcio Roberto Duarte*

Hospital Irmã Dulce, Praia Grande, São Paulo, Brazil

*Corresponding author: Márcio Luís Duarte, Hospital Irmã Dulce, Praia Grande, São Paulo, Brazil, Email: marcioluisduarte@gmail.com

Submission:  December 23, 2017; Published:  January 10, 2018

Abstract

A 69 years-old man with right wrist pain and functional limitations for 06 months. Finkelstein, Tineland Phalantests were negative. Important edema in the wrist and hand at physical examination. Ultrasonography demonstrated pseudoaneurysm with thrombosis in the distal radial artery.

Keywords: Aneurysm, False/diagnostic imaging; Ultrasonography, Doppler; Radial artery

Introduction

Pseudoaneurysm of the upper extremity is rarer as compared to the lower extremity [1]. Pseudoaneurysms of the radial artery are uncommon [2] and they are morphologically characterized as fusiform dilatations, probably representing a form of dissection, with rupture of the artery between media and adventitial layers of the vascular wall or resulting from weakness of the adventitia itself with subsequent capsulation of the perivascular hematoma. Sometimes it is contained in adventitia or adjacent connective tissue issues, promoting local flow, and can cause a series of complications [3].

An arterial pseudoaneurysm or false aneurysms are shaped commonly by penetrating trauma of a native vessel, proceed by hemorrhage and extravasation. Although the detection of such complications may result within hours from the time of insult, they may occur one to several months afterward [2].

Case Report

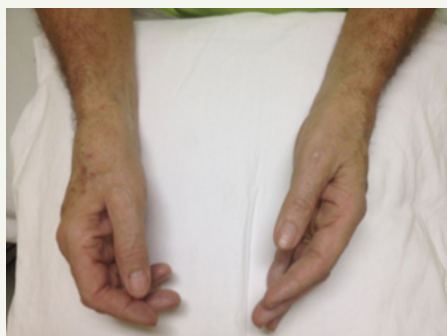

Figure 1: Physical examination comparing wrists and hands, demonstrating pronounced right edema.

A 69 years old man with right wrist pain and functional limitations for 06 months. Finkelstein, Tineland Phalantests were negative. Important edema in the wrist and hand at physical examination (Figure 1). Ultrasonography demonstrated pseudoaneurysm with thrombosis in the distal radial artery (Figures 2 & 3).

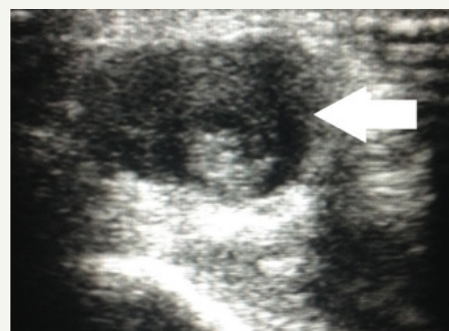

Figure 2: Ultrasonography without Doppler demonstrating thrombosis in the distal radial artery (white arrow).

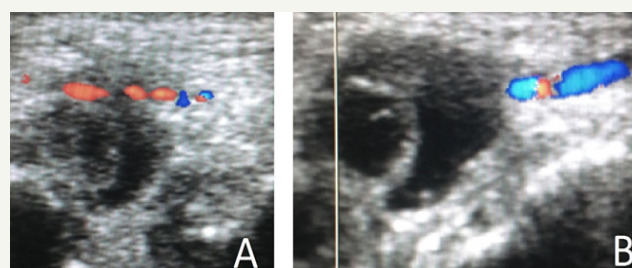


Figure 3: Ultrasonography with Doppler in A and B demonstrating pseudoaneurysm with thrombosis in the distal radial artery.

Discussion

Pseudoaneurysms following arterial injuries are rare occurrences, but they are described in the literature after vascular access attempts to arteriovenous fistulae, catheterization of arteries, arterial blood gas analysis, and other invasive procedures [2]. Normally pseudoaneurysms are associated with multiple attempts of cannulation. May be using an ultrasound for arterial cannulation in high-risk patients might reduce the incidence of pseudoaneurysms as the number of attempts for cannulation is reduced significantly [4].

Depending on the size of the aneurysmsac, a mass might not be palpated leaving pain as the lonely symptom. If a mass can be palpated, it may be pulsatile, but it may not have a thrill. At the physical examination of a pseudoaneurysm, Allen's test is generally negative- arterial pulses are usually palpated distal to the mass. Morbidity can be severe and is related to distal embolization from microemboli, venous compression or even frank rupture [2].

There are three characteristic features of pseudoaneurysms on ultrasound [2]

The presence of expansile pulsatility, detection of turbulent flow that appears as a classic "yin-yang" sign, and a hematoma with variable echogenicity.

A. The variable echogenicity can represent separate episodes of bleeding and rebleeding.

B. The identification of a "to-and-fro" spectral wave form within the neck is considered pathognomonic for a pseudoaneurysm.

Ultrasound compression therapy involves direct ultrasound-guided squeeze of a pseudoaneurysm to obstruct the inflow tract of blood. The stasis of blood promotes coagulation causing occlusion

and resolution of the pseudoaneurysm. Unluckily, compression must behold for over an hour to obtain occlusion- sometimes longer for anticoagulated patients [2].

Surgical intervention may need to be considered if the complete occlusion is not achieved. Another option for occlusion of pseudoaneurysms involves ultrasound-guided thrombin injection into the sac [2].

When progressive thrombosis of the pseudoaneurysm can be demonstrated and there is no enlargement of the pseudoaneurysm and no clinical evidence of pain or neuropathy, such findings portend that the pseudoaneurysm has a tendency to self-heal [5].

Conclusion

Pain can be caused by vascular diseases and it's something that the sonographer doesn't research unless it's on suspicion of requesting physician. The sonographer should look for vascular diseases when there's pronounced edema and pain.

References

1. Kakar BK, Babar KM, Khan A, Naeem M, Khan I, et al. (2006) Surgical experience of post-traumatic pseudoaneurysm of the brachial artery at a tertiary care hospital. *JPMA* 56(9): 409-412.
2. Pero T, Herrick J (2009) Pseudoaneurysm of the radial artery diagnosed by bedside ultrasound. *West J Emerg Med* 10(2): 89-91.
3. Romanus AB, Mazer S, Neto AC, Liu CB, Toni FS, et al. (2002) Pseudoaneurysms- relato de dois casos e revisão da literatura. *Radiol Bras* 35(5): 303-306.
4. Ranganath A, Hanumanthaiah D (2011) Radial artery pseudoaneurysm after percutaneous cannulation using Seldinger technique. *Indian J Anaesth* 55(3): 274-276.
5. Kotval OS, Khoury A, Shah PM, Babu SC (1990) Doppler sonographic demonstration of the progressive spontaneous thrombosis of pseudoaneurysms. *J Ultrasound Med* 9(4): 185-190.