



A Rare Case of Laryngeal Angiomyolipoma



Kanica Chaudhary* and Veena Ramaswamy

HCG Cancer Care Hospital, India

*Corresponding author: Kanica Chaudhary, HCG Cancer Care Hospital, Bangalore, India, Email: drkanicachaudhary@gmail.com

Submission: 📅 January 22, 2018; Published: 📅 March 12, 2018

Introduction

Angiomyolipoma (AML) is a benign mesenchymal neoplasm composed of adipose tissue, blood vessels, and smooth muscle fibres. It is most frequently located in the kidney. The second most common location of the tumor is the liver followed by the abdomen, genital organs, the heart, the mediastinum, lung, skin, head and the neck [1-4]. In the head and neck region, AML has frequently been reported to be located in the oral cavity, nasal cavity, and nasopharynx [1,2,5]. The median age of incidence is 5th decade. Accompanying tuberous sclerosis syndrome is present in 50% of angiomyolipoma patients. AML has been reported in 80% of tuberous sclerosis patients [3]. Only a few laryngeal AML cases are available in the literature [6-8]. The lesion is asymptomatic and usually detected incidentally; may present with difficulty in swallowing. Renal AMLs are often invasive, may involve regional nodes and may recur, while on the contrary, AMLs are most often well circumscribed and easily resected. AML seems to follow an entire benign course.

Case Report

We here in report a case of a 57 year old male with a left tonsillar region swelling discovered accidentally on routine ENT examination 3yrs back; pressing on the left lateral pharyngeal space. On video laryngoscopic examination, two separate masses were found- one in the vallecular and a second one in the epiglottic region. Imaging findings supported the clinical suspicion of an AV malformation/ haemangioma. Both the masses were totally excised by endolaryngeal microsurgery. Grossly, the masses appeared well-circumscribed and globular. On routine haematoxylin and eosin stains, the microscopic examination of the vallecular lesion revealed a well circumscribed lesion formed of thick walled blood vessels with a few thin - walled capillaries. Some of these vessels are seen as slit like vascular spaces and some as cavernous spaces. The stroma in between was composed of smooth muscle bundles and lobules of mature adipocytes. Lymphocytic infiltration in the stroma was noted. The epiglottic lesion showed a vascular lesion composed of interconnecting venules and arterioles of varying sizes. Predominant areas of thrombosed and congested blood vessels, haemorrhage and fibrointimal thickening in the venules were noted. The stroma was oedematous. The epiglottic lesion was an A-V malformation. No evidence of dysplasia or malignancy

was seen in either of the lesions. Immunohistochemistry done on the vallecular lesion showed positive staining for Smooth muscle actin (SMA) and Desmin by the smooth muscle component of the lesion; whereas CD34 was expressed by the vascular endothelial cells. Immunostaining for melanocytic markers like HMB-45 and Melan-A- which signify a renal angiomyolipoma – was negative. Morphologic and immunohistochemical findings were concordant for the diagnosis of an angiomyolipoma of the vallecular.

Discussion

Angiomyolipoma is a rare benign mesenchymal tumor composed of varying proportions of mature lipid tissue, smooth muscle fibres, and vessels with thick walls. It is most commonly seen in women. While 50% of renal angiomyolipoma cases are seen together with tuberous sclerosis syndrome, extra-renal cases are sporadic [9]. There were no additional findings suggesting tuberous sclerosis- like mental retardation, epilepsy, and cutaneous lesions such as adenoma sebaceum in our case. Endoscopic preoperative histopathologic diagnosis is difficult due to the sub mucosal development of the tumor. Other tumors of adipose tissue like angioliopoma, liposarcoma and angioleiomyoma should initially be taken into consideration in the microscopic differential diagnosis. Angioliopoma lacks myoid differentiation. Lipoid component does not exist in an angioleiomyoma. In a liposarcoma, lipoid component must be searched carefully for lipoblasts.

Conclusion

The above diagnosis of Angiomyolipoma was made on the basis of both morphology and Immunohistochemistry. The case is being presented for its rarity on presenting within the larynx.

References

1. Piattelli A, Fioroni M, Rubini C, Fiera E (2001) Angiomyolipoma of the palate. Report of a case. *Oral Oncol* 37(3): 323-325.
2. Yamamoto K, Nakamine H, Osaki T (1995) Angiomyolipoma of the oral cavity. Report of two cases. *J Oral Maxillofac Surg* 53(4): 459-461.
3. Ito M, Sugamura Y, Ikari H, and Sekine I (1998) Angiomyolipoma of the lung. *Arch Pathol Lab Medi* 122(11): 1023-1025.
4. Watanabe K, Suzuki T (1999) Mucocutaneous Angiomyolipoma: a report of 2 cases arising in the nasal cavity. *Arch Pathol Lab Med* 123(9): 789-792.

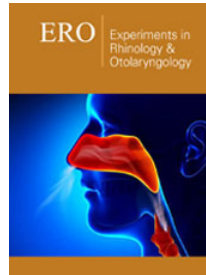
5. Ide F, Shimoyama T, Horie N (1998) Angiomyolipomatous hamartoma of the tongue. *Oral Surg Oral Med Oral Pathol Oral Radiol Endod* 85(5): 581-584.
6. Stodulski D, Stankiewicz C, Rzepko R, Kowalska B (2007) Angiomyolipoma of the larynx: case report. *Eur Arch Otorhinolaryngol* 264(1): 89-92.
7. Durgun Y, Firat C, Miman MC, Kirimlioglu H (2010) A rare benign laryngeal tumor Angiomyolipoma. *J Craniofac Surg* 21(6): 1956-1957.
8. Bandhlish A, Leon Barnes E, Rabban JT, McHugh JB (2011) Perivascular epithelioid cell tumors (PEComas) of the head and neck: report of three cases and review of the literature. *Head and Neck Pathol* 5(3): 233-240.
9. Tseng CA, Pan YS, Su YC, Wu DC, Jan CM, et al. (2004) Extrarenal retroperitoneal Angiomyolipoma: case report and review of the literature. *Abdominal Imaging* 29(6): 721-723.



Creative Commons Attribution 4.0
International License

For possible submissions Click Here

[Submit Article](#)



Experiments in Rhinology & Otolaryngology

Benefits of Publishing with us

- High-level peer review and editorial services
- Freely accessible online immediately upon publication
- Authors retain the copyright to their work
- Licensing it under a Creative Commons license
- Visibility through different online platforms